

# Subfascial Breast Augmentation: Theme and Variations

**Richard A. Baxter, MD**

Dr. Baxter is in private practice in Mountlake Terrace, WA.

**Background:** Subfascial placement of breast implants for augmentation has been advocated as an option that has some of the advantages of both the subpectoral and subglandular approaches while minimizing the disadvantages of each.

**Objective:** The author reports on the use of the subfascial approach in athletic and thin individuals, including extension of the range of applications for this approach through the use of partial muscle flaps for upper pole coverage.

**Methods:** A periareolar approach was preferred, particularly when segmental muscular flaps were incorporated into the augmentation. Medially-based flaps supplied by the intercostal perforators were used to achieve greater upper-pole coverage, which can be particularly beneficial when using high-profile implants. Conversion from dual-plane submuscular to subfascial placement was used for correction of a "dynamic" breast (a breast that is distorted with muscle activity) or related contour deformity.

**Results:** Examples of the range of applications of the subfascial approach are presented, including use of small and larger segmented muscle flaps and correction of the dynamic breast or contour deformity.

**Conclusions:** Use of the subfascial approach, with selective application of segmented muscle flaps, can help reduce reoperation rates after breast augmentation. (*Aesthetic Surg J* 2005;25:447-453.)

Despite advances in surgical techniques and implant design and manufacturing standards, breast augmentation remains a procedure in evolution. The judgment as to which type and size of implant to use and the plane of placement for each patient is an exercise in balancing a number of often competing factors. Implant–soft tissue interactions, the patient's physical characteristics, her expectations, and lifestyle factors all influence the decision process and outcome.

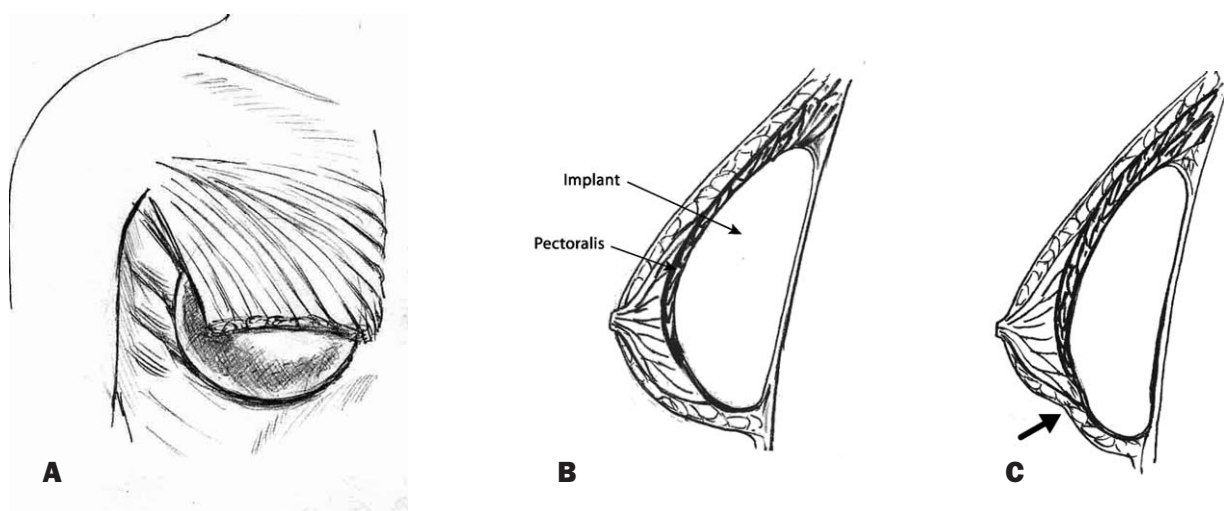
These issues are particularly highlighted in the treatment of athletic individuals and those with minimal soft-tissue thickness for implant coverage. Subfascial placement has been advocated as a compromise option for individuals such as these, as well as for others for whom traditional methods present unacceptable trade-offs.<sup>1-4</sup> Variations on the subfascial technique, incorporating partial muscle coverage, allow customization of the technique for prevention as well as correction of specific deformities.

Submuscular placement has become the most common plane for implant placement in the United States.<sup>5</sup> This is likely related to restrictions on the use of silicone gel-filled implants, as the tissue coverage afforded by the pectoral muscle is felt to be advantageous with the less natural-feeling saline-filled prosthesis. Subpectoral place-

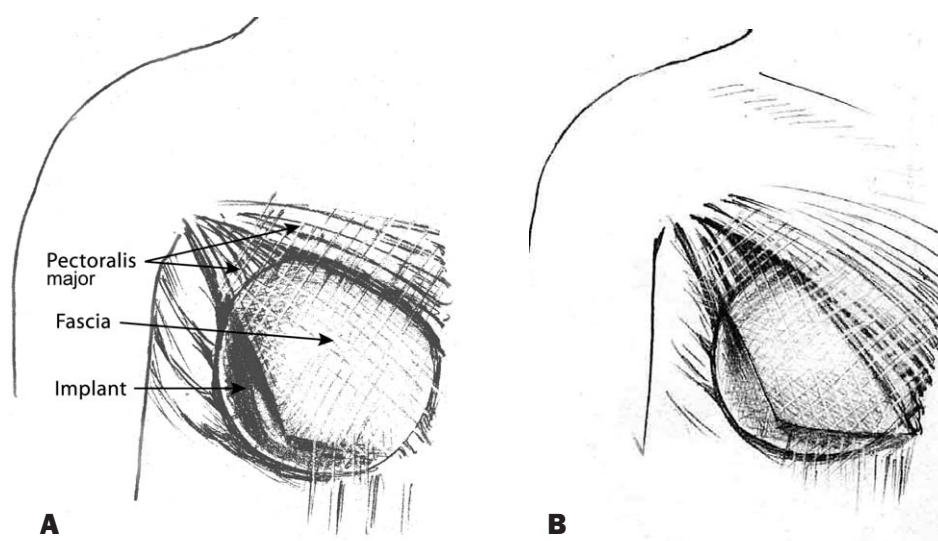
ment also helps prevent upper-pole step-off deformity, camouflages rippling, improves mammographic visualization, and minimizes risk of sensory disturbances to the nipple-areolar complex.<sup>6-9</sup>

Subglandular placement, on the other hand, has the advantages of easier dissection, more rapid recovery, and possibly improved aesthetics in the ptotic breast, though this latter point is a subject of debate. Further, the theoretic disadvantage from compromised mammographic surveillance has not translated into adverse clinical manifestations.<sup>10</sup>

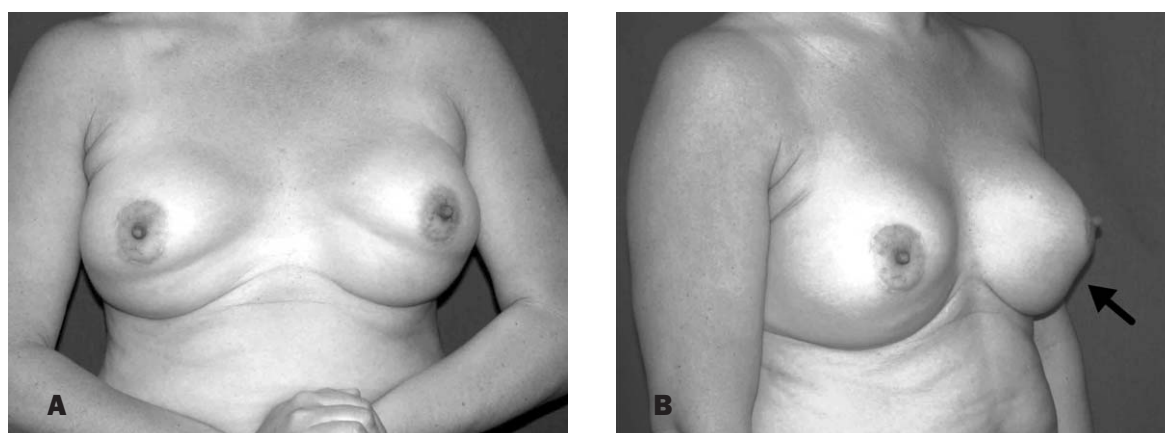The most commonly applied strategy for submuscular implant placement appears to be the "dual plane" procedure<sup>8</sup> and related techniques involving the release of the inferior origin of the pectoral muscle, along with variable degrees of medial release. This free-muscle edge, therefore, becomes fused with the anterior capsule at the junction of the submuscular and subglandular planes (*Figure 1*). These maneuvers are necessitated by the usual origin of the muscle above the level of the inframammary fold; without detachment, optimal implant positioning would be impossible in most cases. Even with adequate release, however, dynamic muscle action may result in implant displacement and subsequent malposition.



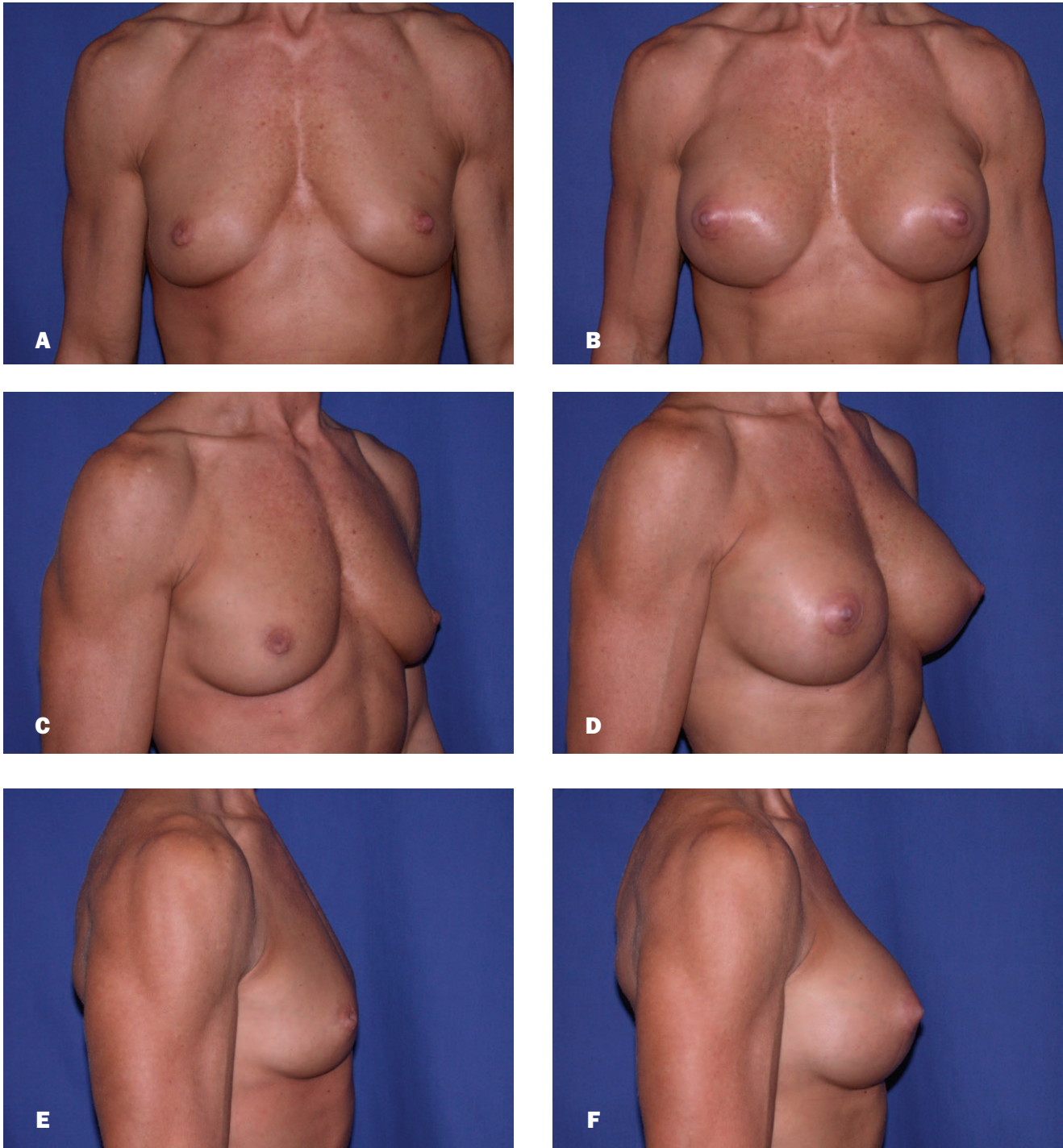
**Figure 1.** Dual-plane subpectoral augmentation. **(A)**, Note the free edge of the pectoralis muscle, which is fused with the anterior capsule above the inframammary fold **(B)**. **C**, Contraction of the muscle distorts the breast as the muscle pulls against the capsule.



**Figure 2.** Schematic view of subfascial placement with a small flap **(A)** for enhanced upper pole coverage, and a larger flap **(B)** based on the medial portion of the pectoralis muscle origin. In both cases, the transverse portion of the muscle attachment to the chest wall is intact behind the implant.



**Figure 3.** **A**, The "dynamic" breast is characterized by distortion with contraction of the pectoral muscle, the edge of which can be seen as a line across the lower portion of the breast. **B**, This may correspond to a visible contour defect (arrow).

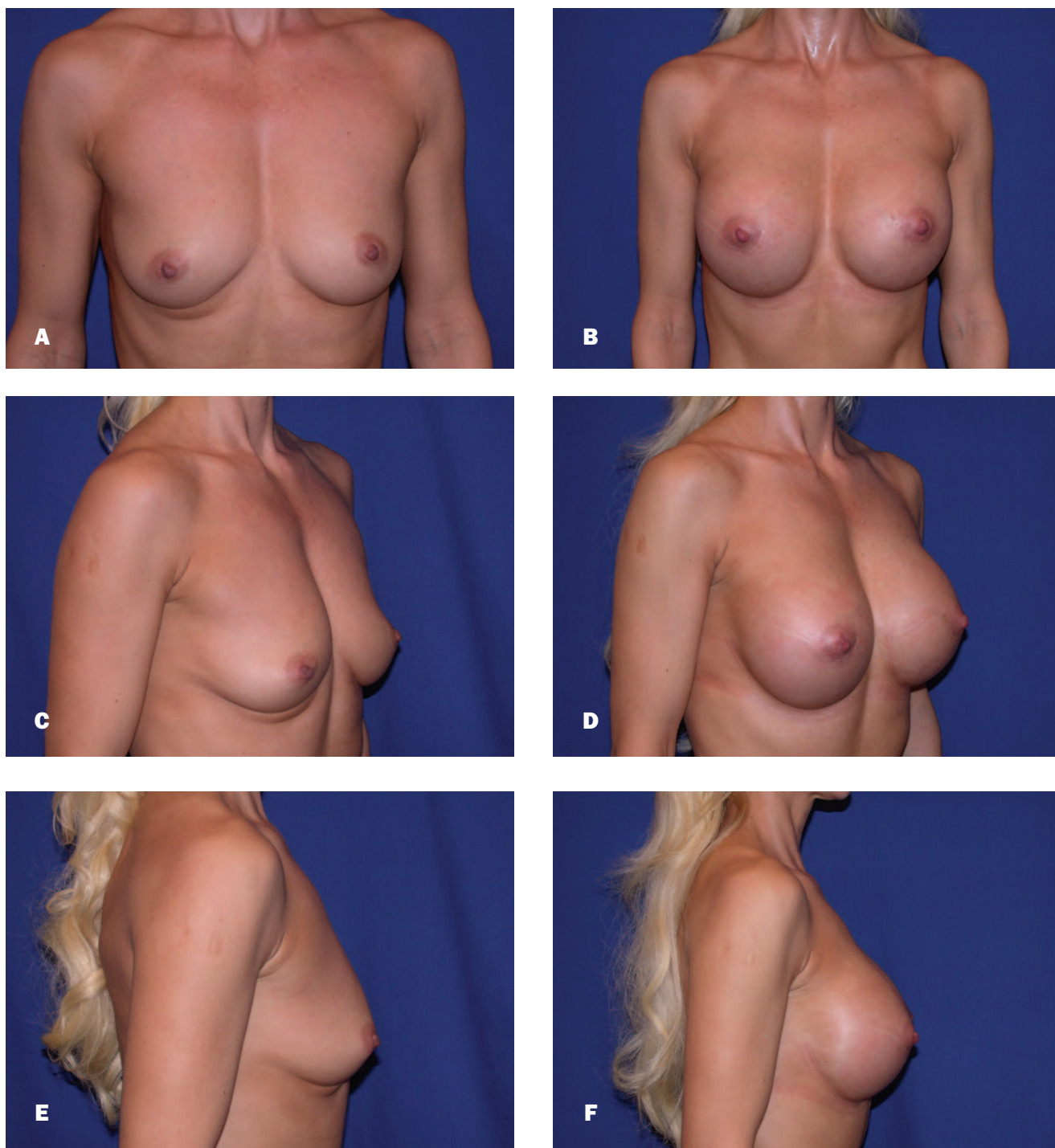

**Figure 4.** A, C, E, Preoperative views of a 46-year-old competitive bodybuilder with low body fat and highly developed musculature. B, D, F, Postoperative views 3 weeks after subfascial augmentation with McGhan style 40 360-cc implants.

A rarely discussed sequela of dual-plane augmentation is the “dynamic breast,” manifested by distortion of the breast with muscle activity.<sup>6,11</sup> One reason for the lack of attention to this problem may be the difficulty in measuring it objectively, as it likely occurs to some degree with all

dual-plane augmentations. It is of particular concern in athletes and patients with low body fat who need enhanced implant concealment but for whom any degree of breast distortion with muscle activity is unacceptable. Subfascial placement is a compromise option for these patients.





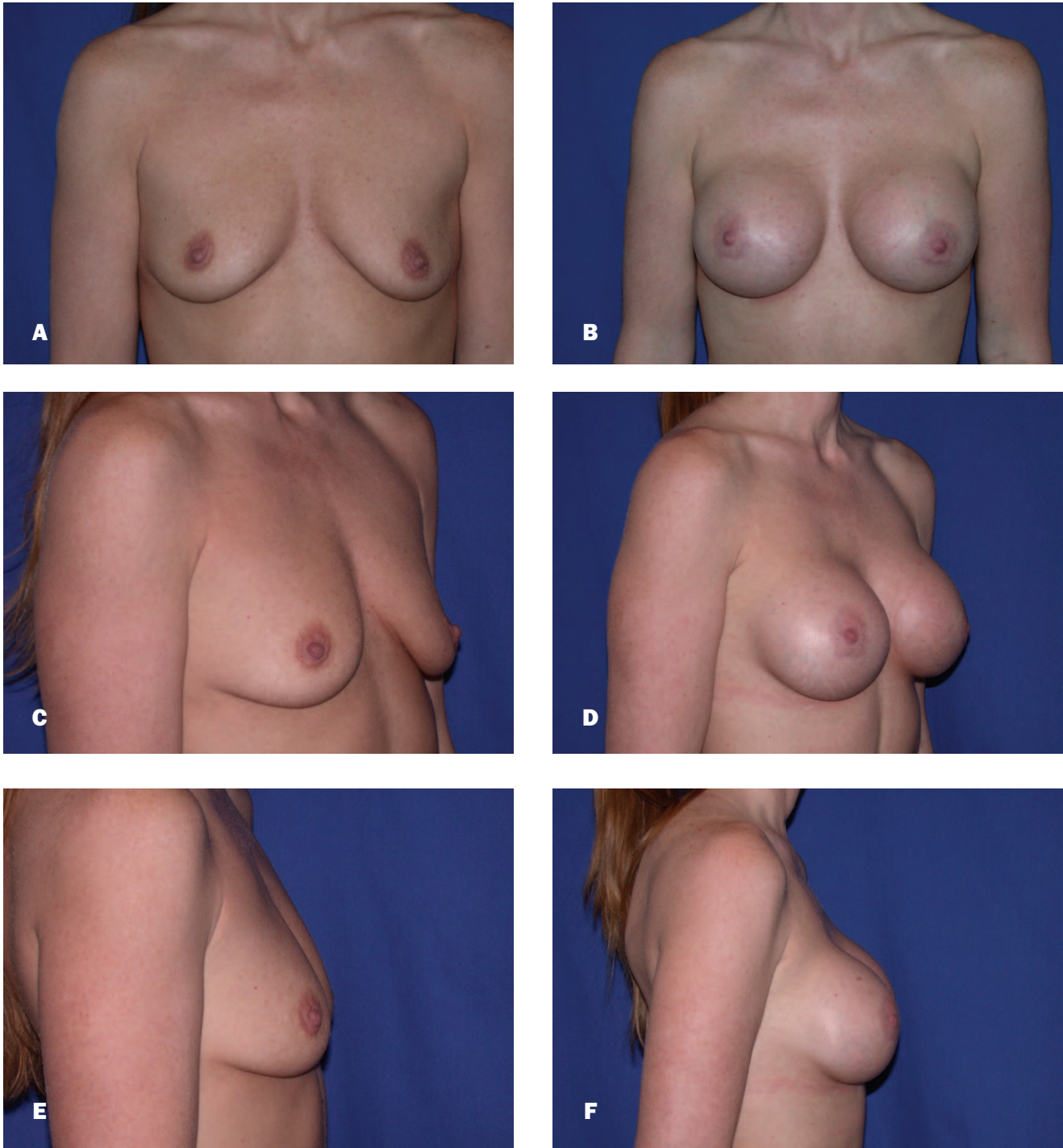
**Figure 5.** A, C, E, Preoperative views of a 42-year-old fitness competitor. B, D, F, Postoperative views 3 weeks after subfascial augmentation with McGhan style 20 (high-profile) 375-cc implants, incorporating a small muscle flap for upper pole coverage.

Variations incorporating segmental portions of the muscle are often useful and extend the range of application for the technique. This flap is similar in concept to the “trapdoor” flap described by Collis et al,<sup>12</sup> but differs in that it is developed with a muscle-splitting technique and is continuous

with the upper portion of the implant pocket.

#### **Anatomy and Surgical Technique**

The pectoralis fascia is relatively thin over the lower portion of the muscle, becoming more substantial superior-

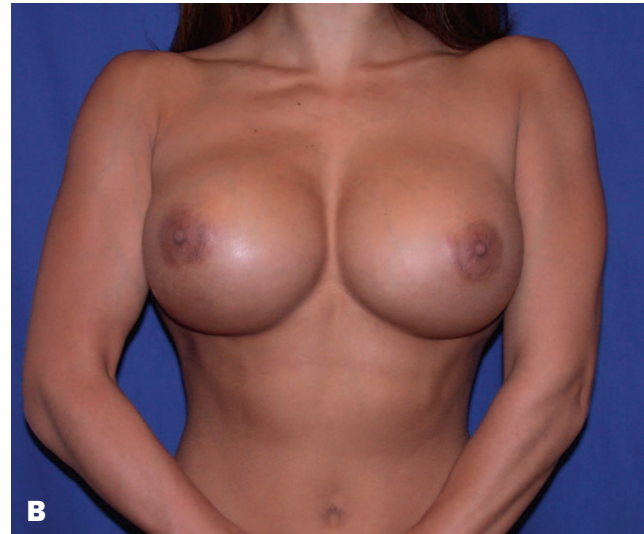
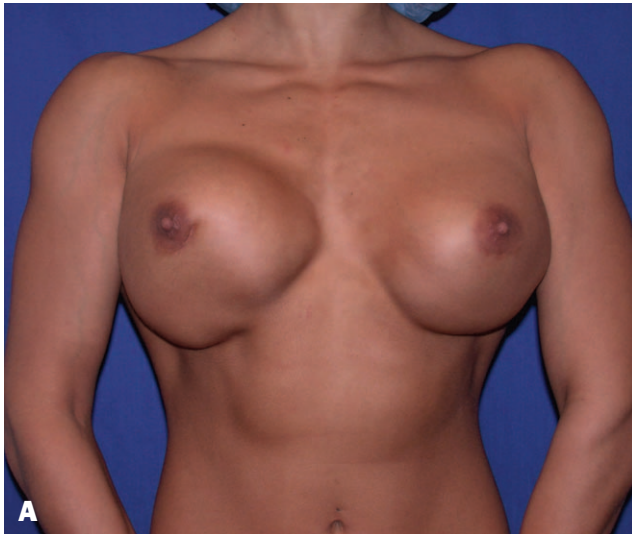
**Figure 6. A, C, E,** Preoperative views of a 38-year-old woman. **B, D, F,** Postoperative views 2 months after subfascial augmentation with McGhan style 68HP implants, 375-cc fill volume. A larger muscle flap was utilized for upper pole transition, better coverage of saline implants, and elimination of the possibility of dynamic distortion with muscle flexion.

ly.<sup>1</sup> Consequently, upper-pole coverage with the subfascial plane may approximate the appearance of submuscular coverage for the average patient. The fascia can be readily raised from either the axillary, periareolar, or inframammary approaches, though my preference is periareolar,

especially when incorporating segmental muscle flaps. As this plane is relatively vascular, the use of electrocautery for the dissection is recommended. The fascia overlying the precostal portion of the rectus abdominis muscle can be elevated, if necessary or desired, for lower pole coverage.





**Figure 7.** Correction of a dynamic breast or related contour deformity. **A**, Preoperative view of a 29-year-old fitness model. **B**, Postoperative view 3 weeks after placement of Mentor style 350, 600-cc subpectoral implants in the subfascial plane with a small upper pole muscle flap. Both photos demonstrate active flexion.

Some patients may benefit from greater upper-pole coverage than is provided by the fascia alone, particularly with the use of high-profile implants due to the more acute angle from the chest wall to the upper breast. In these cases, a medially-based segmental muscle flap supplied by the intercostal perforators may be deployed. This can be performed at any level by splitting the pectoral muscle along its fibers. Often only a thin strip of muscle along the upper edge of the pocket is required (Figure 2, A), while the entire medial portion can also be used by dividing the muscle along its median raphe (Figure 2, B). It should be noted that the muscle becomes more vascular closer to the axilla, necessitating meticulous hemostasis. By dividing the muscle longitudinally at various levels depending on circumstances, a continuum between dual-plane submuscular and subfascial placement is established, as all or some of the implant is subfascial and some or none is submuscular.

The dynamic breast (Figure 3, A) is often accompanied by a contour irregularity on the lower pole of the breast (Figure 3, B). Operative dissections have confirmed that this usually corresponds to the area where the detached muscle origin has fused with the anterior capsule (Figure 1, C). Conversion from dual-plane submuscular to subfascial placement can therefore be used for the correction of either a dynamic breast or related contour deformity. The muscle is mobilized and sutured to the posterior capsule using #00 absorbable sutures, leaving the fascia anterior. I use suction drains for 24 to 48 hours in these cases, but not routinely in primary augmentations. Patients are instructed to avoid lifting for 6 weeks.

## Results

Figures 4 to 7 illustrate the range of applications of the subfascial approach and its variations. The patient in Figure 4 is a competitive bodybuilder with low body fat and highly developed musculature who received McGhan style 40 360-cc implants using a subfacial approach. Submuscular placement would have likely resulted in severe distortion, while subglandular placement would have afforded too little coverage.

Subfascial augmentation incorporating a small upper flap for upper pole coverage is illustrated in Figure 5. The patient is a fitness competitor who received McGhan style 20 (high-profile) 375-cc implants selected for base-diameter matching on her relatively narrow chest. The small flap provided a smoother transition from the chest wall to the augmented breast.

The use of a larger muscle flap (see Figure 2, B) for upper pole transition, better coverage of saline implants, and elimination of the possibility of dynamic distortion with muscle flexion is shown in Figure 6. The patient received McGhan style 68HP implants, 375-cc fill volume.

Correction of a dynamic breast or related contour deformity is illustrated in Figure 7. The patient is a fitness model who received Mentor style 350 600-cc subpectoral implants. The photographs demonstrate active flexion before and after implant placement in the subfascial plane, using a small upper-pole muscle flap.

## Discussion

Proponents of the subfascial technique<sup>1-4</sup> have generally used shaped cohesive gel implants (Inamed, Santa

Barbara, CA). The use of segmental muscle flaps may improve the suitability of the subfascial technique for saline implants and round implants of any type. I generally prefer the round implants, as they establish a natural-appearing profile in both the upright and supine positions,<sup>13</sup> while allowing for optimal base-diameter matching.<sup>14</sup> Implantation of high-profile implants may particularly benefit from the use of a segmental muscle flap when placed subfascially, because of the less obtuse angle from the chest wall to the upper pole.

## Conclusion

Reoperation rates following breast augmentation have remained high despite advances in implant technology and surgical technique.<sup>15,16</sup> I believe that the subfascial technique is versatile, useful, and can contribute to reducing the need for revision. The dynamic breast from dual-plane augmentation is one contributing factor to reoperation that can be minimized by judicious use of the subfascial technique. With the selective application of segmental muscle flaps for upper-pole coverage, factors such as the step-off deformity and unnatural-appearing implant contours can also be reduced. I now use the subfascial approach increasingly for primary augmentation as well as for revision cases. ■

## References

1. Graf R, Bernardes A, Ripplel R, et al. Subfascial breast implant: a new procedure. *Plast Reconstr Surg* 2003;111:904-908.
2. Góes JCS, Landecker A. Optimizing outcomes in breast augmentation: seven years of experience with the subfascial plane. *Aesthetic Plast Surg* 2003;27:178-184.
3. Graf RM, Bernardes A, Auersvald A, et al. Subfascial endoscopic transaxillary augmentation mammoplasty. *Aesthetic Plast Surg* 2000;24:216-220.
4. Stoff-Khalili MA, Schoze R, Morgan WR, et al. Subfascial periareolar augmentation mammoplasty. *Plast Reconstr Surg* 2003;114:1280-1288.
5. Past breast information and breast implants poll results, 2000. Breast augmentation and breast implants information web. Available at: [www.implantinfo.com/pollcenter/pastresults.htm](http://www.implantinfo.com/pollcenter/pastresults.htm). Last accessed March 25, 2005.
6. Lille S, Perumean J, McArthur E. The role of releasing the inferior-medial pectoralis muscle in submuscular breast augmentation [letter]. *Plast Reconstr Surg* 2003;112:919.
7. Schlenz I, Kuzbari R, Gruber H, et al. The sensitivity of the nipple-areolar complex: an anatomic study. *Plast Reconstr Surg* 2000;105:905-909.
8. Tebbetts J. Dual plane breast augmentation: optimizing implant-soft tissue relationships in a wide range of breast types. *Plast Reconstr Surg* 2001;107:1255-1272.
9. Handel N, Silverstein MJ, Gamagami P, et al. Factors affecting mammographic visualization of the breast after augmentation mammoplasty. *J Am Med Assoc* 1992;268:1913-1917.
10. Miglioretti DL, Rutter CM, Geller BM, et al. Effect of breast augmentation on the accuracy of mammography and cancer statistics. *J Am Med Assoc* 2004;291:442-450.
11. Tofield JJ. Dual plane breast augmentation. *Plast Reconstr Surg* 2001;108:2162.
12. Collis N, Platt AJ, Batchelor AG. Pectoralis major "trapdoor" flap for silicone breast implant medial knuckle deformities. *Plast Reconstr Surg* 2001;108:2133-2135.
13. Hamas RS. The postoperative shape of round and teardrop saline-filled breast implants. *Aesthetic Surg J* 1999;19:369-374.
14. Baxter RA. Indications and practical applications for high-profile saline breast implants. *Aesthetic Surg J* 2004;24:24-27.
15. Saline-filled breast implants: making an informed decision. Santa Barbara (CA): Inamed Corp; 2005. p. 16.
16. Mentor Corporation. Saline-filled breast implant surgery: making an informed decision. Santa Barbara (CA): Mentor Inc; 2002.

Accepted for publication July 7, 2005.

Reprint requests: Richard A. Baxter, MD, 6100 219<sup>th</sup> Street SW, Suite 290, Mountlake Terrace, WA 98043.

Copyright © 2005 by The American Society for Aesthetic Plastic Surgery, Inc. 1090-820X/\$30.00

doi:10.1016/j.asj.2005.07.006