

## Controlled Results with Abdominoplasty

Richard A. Baxter, M.D., F.A.C.S.

Mountlake Terrace, WA, USA

**Abstract.** An approach to abdominoplasty has been developed incorporating a series of key surgical maneuvers designed to minimize complications while controlling scar position and eliminating the need for long-term drains. These include sharp defatting of the layer deep to the superficial fascia, progressive tension anchor sutures from the flap to the rectus sheath, and anchor sutures from the superficial fascia to the deep fascia along the line of closure. A retrospective review shows that the rate of postoperative seromas decreased from 33% to 6% with the use of anchor sutures from the flap to the deep fascia.

**Key words:** Abdominoplasty—Seroma

### Introduction

Improvements in surgical technique have created justifiably high expectations for body contouring surgery. Variations on the basic abdominoplasty operation have enabled the operative design to be tailored to the individual's morphology. However, problems of postoperative scar position shifting, excess elevation of the pubic escutcheon, seromas, and other factors limit the success of the standard abdominoplasty for some patients. This paper reviews the author's experience with a flexible approach incorporating a series of key maneuvers. These include sharp defatting of the layer deep to the superficial fascia, progressive tension anchor sutures in the midline and paramedian areas to distribute tension, and anchor sutures from the superficial fascia on the to the deep fascia along the line of closure. With proper planning and execution, these techniques enable the surgeon to control long-term position of the scar with a high degree of

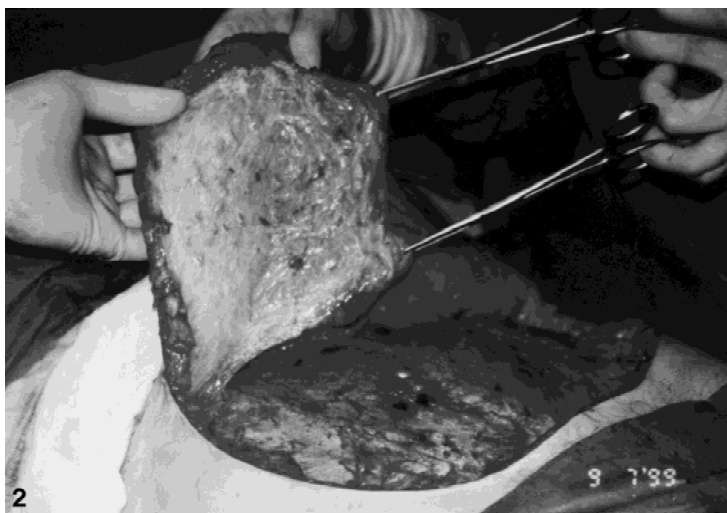
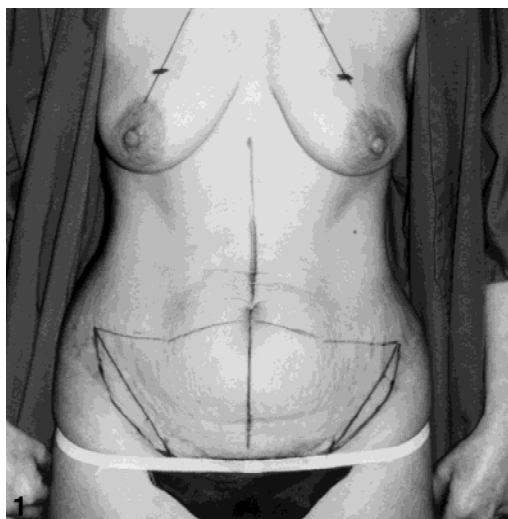
precision, while minimizing the skin tension along the line of closure. Seromas are minimized by the progressive tension anchor sutures, which help eliminate the dead space and facilitate apposition of the flap to the muscle fascia, without the use of long-term drains.

### Methods

#### *Patient Selection*

Until a means of controlled nonsurgical skin retraction in conjunction with lipocontouring and diastasis repair is developed, dermolipectomy will be indicated for many patients. Prior pregnancy, significant weight loss, and poor skin tone are usual predisposing factors. It is imperative to recognize hernias preoperatively so that they can be appropriately treated in the surgical plan; however, unexpected hernias may be encountered intraoperatively. Lipoplasty in a patient with poor skin tone results in disappointing outcomes and frequent need for additional surgery. If the poor skin tone is limited to the infraumbilical region and/or the immediate supraumbilical area, then a mini-abdominoplasty may be indicated [2]. Selective use of the umbilical float technique should be considered. A full standard abdominoplasty is the most commonly indicated option for patients with striae distensae and skin laxity.

Abdominoplasty is not a recommended procedure for patients with obesity. Smokers are at increased risk for ischemic complications, and it is wise to decline to perform the procedure on tobacco users who are unable or unwilling to quit. Patients who have had a laparotomy via a subcostal incision are also at risk for compromise of the flap, but this is not an absolute contraindication if the desired result can be achieved with minimal flap tension. Midline scars limit flap advancement unless they are confined to the infraumbilical region and can be completely excised.



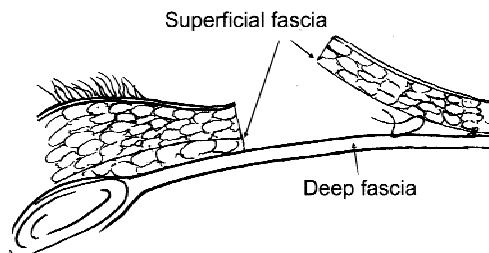
**Fig. 1.** Preoperative markings (The patient is also marked for a mastopexy).  
**Fig. 2.** The flap is defatted along the deep aspect of the superficial fascia.

*Preoperative Marking*

The patient should be marked in the standing position prior to surgery. This allows for an accurate assessment of the amount of elevation of the anterior thighs and suprapubic area that is desired, as well as an estimate of the amount of advancement of the flap. The author's preference is for a low straight horizontal scar across the suprapubic area, then angling superolaterally above the anterior superior iliac spines (Fig. 1). The markings are designed to place maximal tension centrally. An inverted obtuse "V" about the umbilicus connects with arches extending laterally to the planned endpoint of the scar; the anterior upper thigh area has an opposite curve (of larger radius but approximately the same length), so that the two curves will appose resulting in a straight line closure. The upper line needs a smaller radius in order to equal the length of the lower lateral segment. The length of the two limbs of the "V" should equal the transverse line across the suprapubic region. Areas for adjunctive liposuction laterally and in the precostal area are also marked.

*Technique*

The key maneuvers in this method follow: (1) make the lower incision first, and do not commit to the upper incision until after undermining, (2) undermining is done judiciously and perforating neurovascular structures are preserved by discontinuous undermining where possible, (3) the entire adipose layer deep to the superficial fascia is sharply excised, (4) tension on the flap is distributed by suturing the superficial fascia on the underside of the flap to the deep fascia (rectus sheath), (5) the precise level and direction of the line of closure is controlled by suturing the approximated superficial fascia to the deep fascia, (6) a transverse or inverted "V" incision for in-

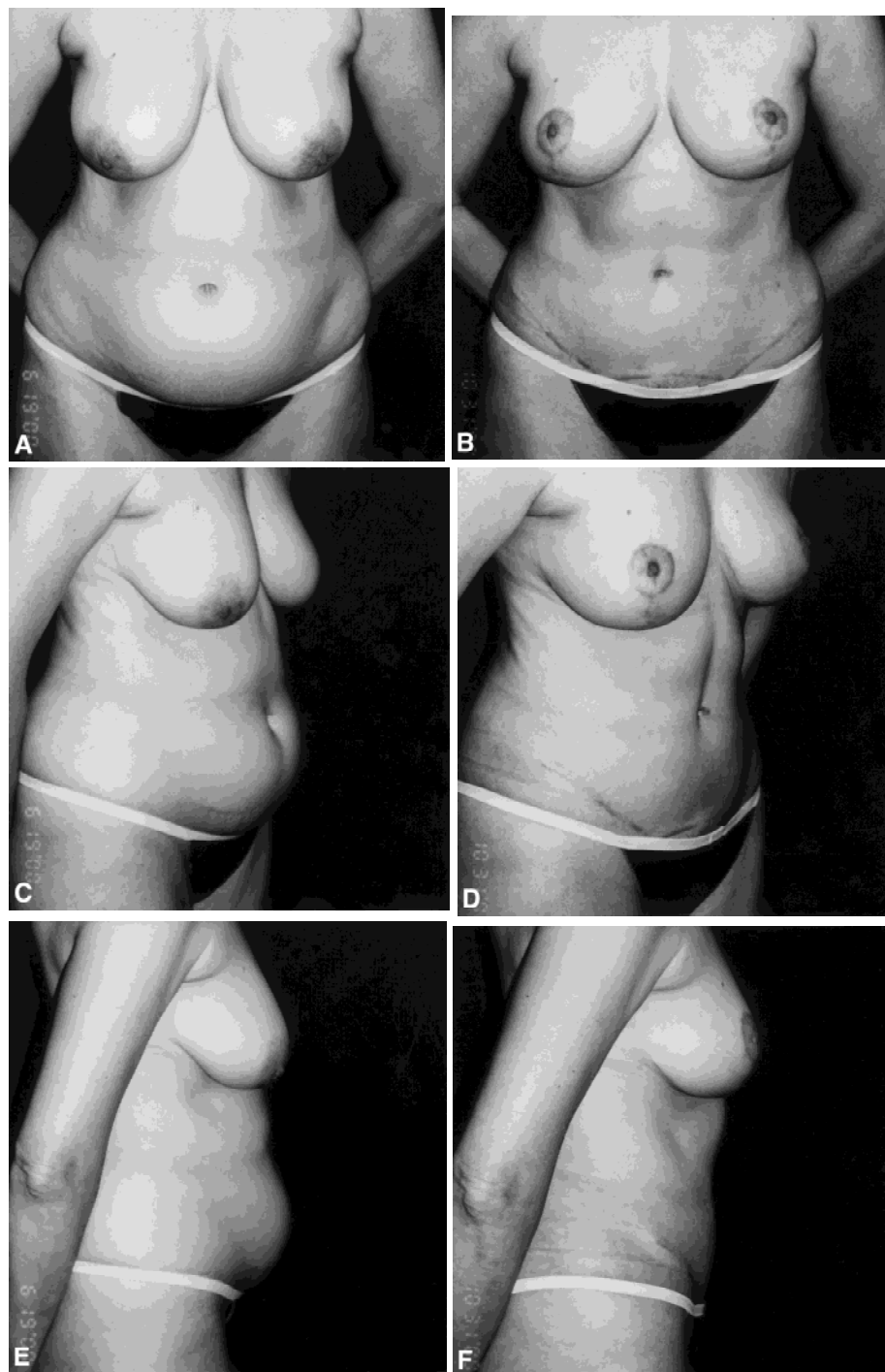


**Fig. 3.** Anchor suture placement. Each suture contributes to flap advancement.

setting of the umbilicus adds 1–1.5 cm of flap advancement where necessary.

By making the lower incision first, a commitment is made to place the scar at the desired location, rather than risking having to place it too high. The degree of elevation, if any, of the pubic area is determined at this time. The amount of elevation will be controlled by the anchor sutures from the superficial to the deep fascia along the line of closure, not by the tension on the flap. The upper incision will be made either at the premarked level, or adjusted depending upon tension, after the flap is undermined, defatted, and advanced with progressive tension sutures to the level of the umbilicus. It is usually better to close the umbilical opening vertically above the transverse scar, rather than having the entire scar too high. This is rarely necessary, however, as the sequential anchoring sutures often enable more flap advancement, with evenly distributed tension, than was predicted.

Careful undermining laterally may identify neurovascular bundles, which can be isolated and preserved, enhancing both sensory preservation and circulation to the flap. This is well worth the few extra minutes it takes. Generous plication of the rectus fascia with nonabsorbable braided sutures is done according to the surgeon's judgment. The fat layer deep to Scarpa's fascia can be

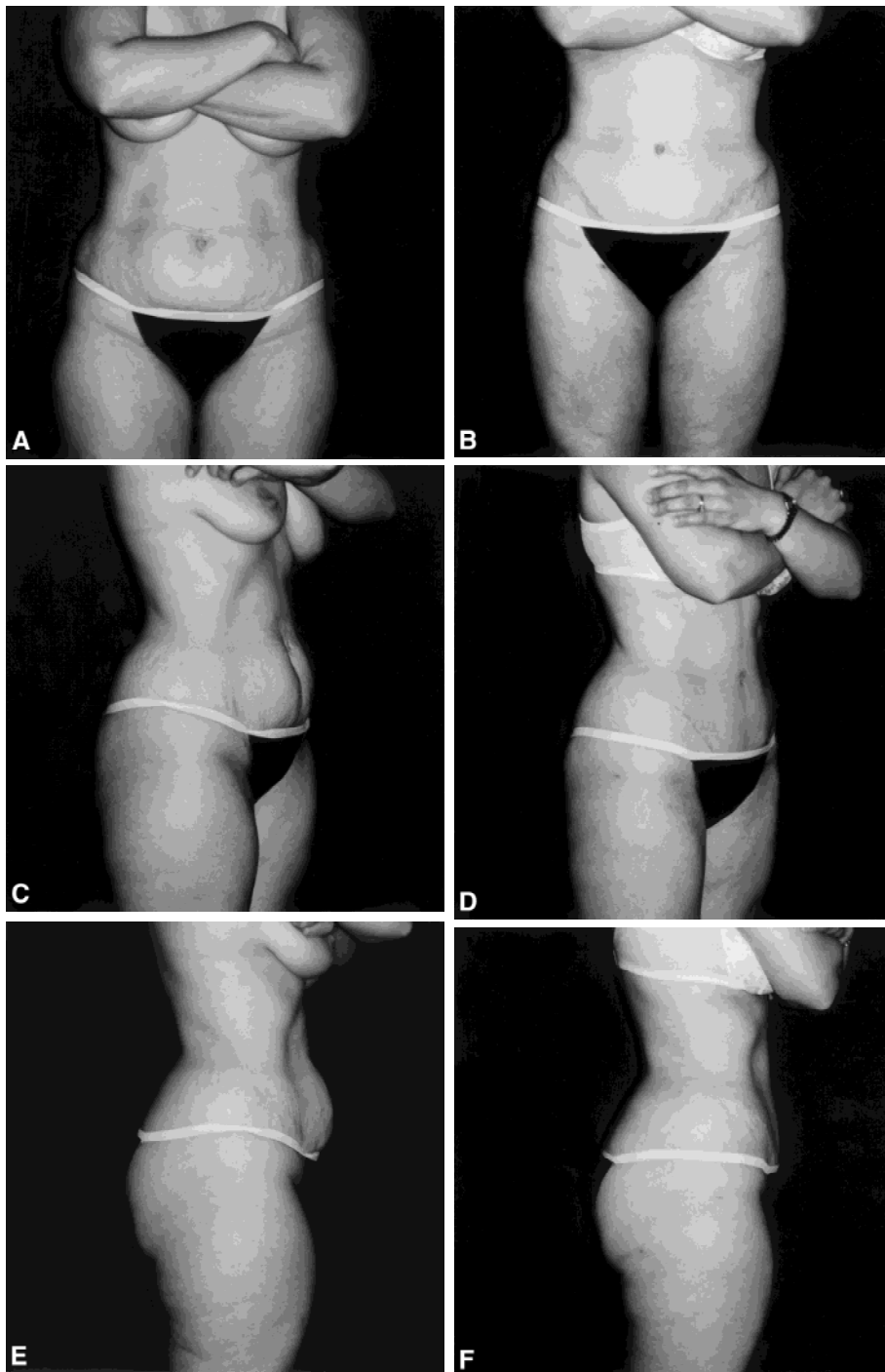


**Fig. 4.** Preoperative views (A, C, E). Postoperative views (B, D, F). Note the midline groove created by progressive tension anchor sutures.

completely excised by dissection along the relatively avascular plane on the deep aspect of the fascia (Fig. 2). While it may be desirable to treat the transition zones laterally with liposuction, it is not usually necessary to suction the superficial layer within the flap. This also avoids unnecessary trauma to the superficial vasculature.

The exposed superficial fascial layer on the undersurface of the flap provides a strong structure upon which to distribute tension on the flap. This is done by suturing the

flap to the deep fascia in the midline and paramedian areas, beginning in the supraumbilical area (Fig. 3). Absorbable sutures such as OO polydioxanone are used. After inseting the umbilicus at the proper level, the anchor sutures are continued in sequence. Midline progressive tension sutures also help create an attractive groove (Figs. 4D, 5D, 6D). The final decision about trimming the flap may be deferred until this time if there is any uncertainty about the amount of tissue to be excised. The



**Fig. 5.** Preoperative views (A, C, E). Postoperative views (B, D, F).

anchor sutures serve to eliminate seromas by closing off the “dead space” and shift the tension from the skin to the fascia.

Approximation of the superficial fascia [4] will minimize tension on the skin edges along the line of closure, but the ultimate configuration of the scar will be determined by the balance of tension across the scar unless it is fixed to the deep fascia (rectus sheath centrally, exter-

nal oblique fascia laterally). The scar may migrate, resulting in asymmetry, excessive elevation of the pubic area, or undesirable shape or position. These problems are prevented by anchoring the superficial to deep fascia along the line of closure (Fig. 7); thus the final configuration of the scar is determined not by balanced tension, but rather by the desired amount of movement of the tissue on either side. For example, it may be desirable to

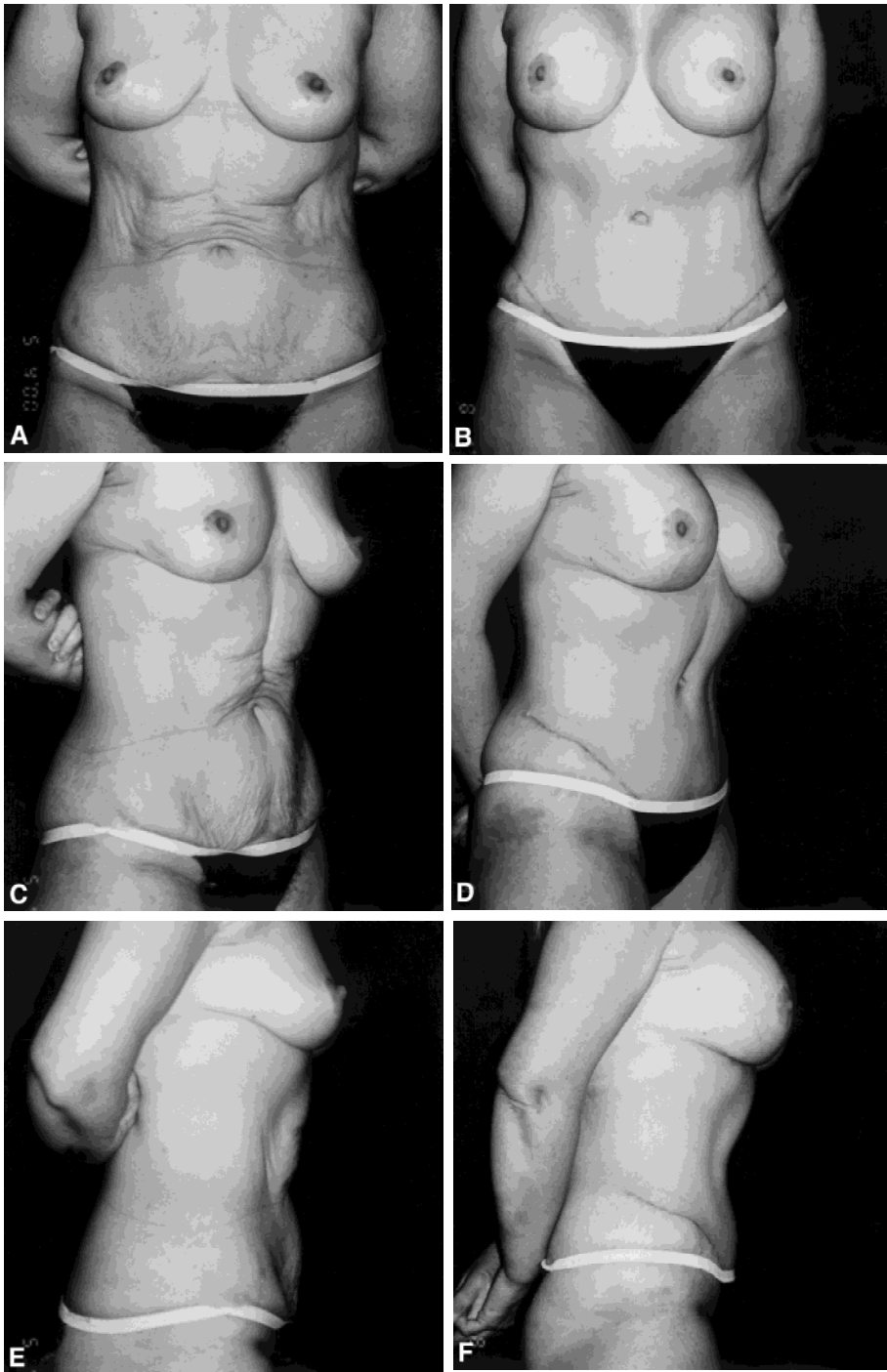


Fig. 6. Preoperative views (A, C, E). Postoperative views (B, D, F). The patient has also had a breast augmentation.

maximize elevation of the anterior thigh, while minimizing pubic elevation and keeping the abdominal flap tension acceptable. The deep fascia provides a solid foundation for securing the orientation of the surface scar. Anchoring sutures may also be helpful in the correction of scar migration deformities (Fig. 8).

Electrocautery is used for hemostasis. The operating table may be flexed at the patient's hips to help determine the best line of excision after flap undermining. Often a "dog ear" excision is required, although it may be best in some cases to defer this to a later date and

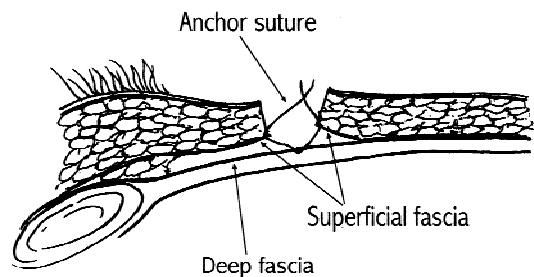
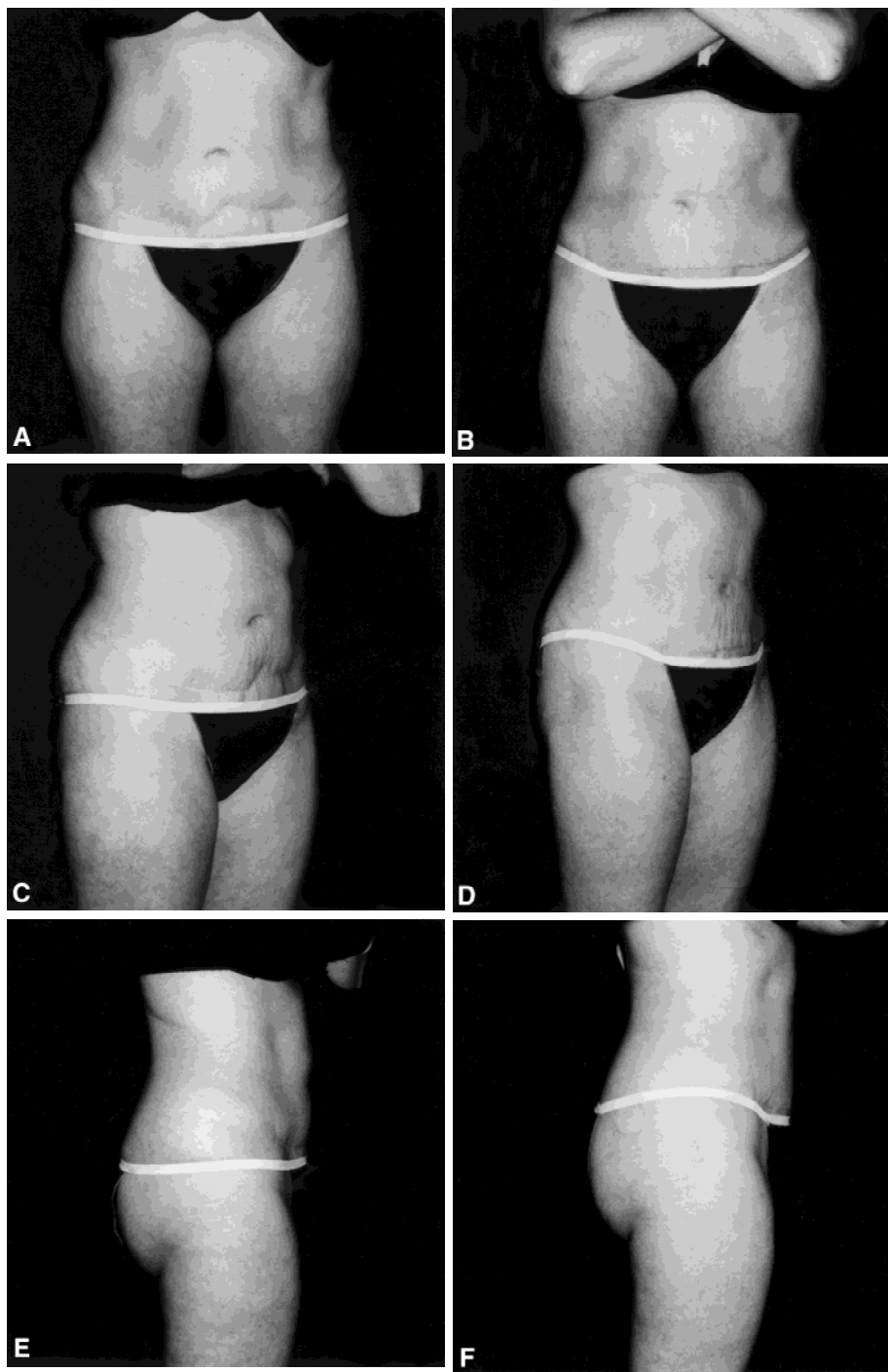


Fig. 7. Anchor sutures along the line of closure.

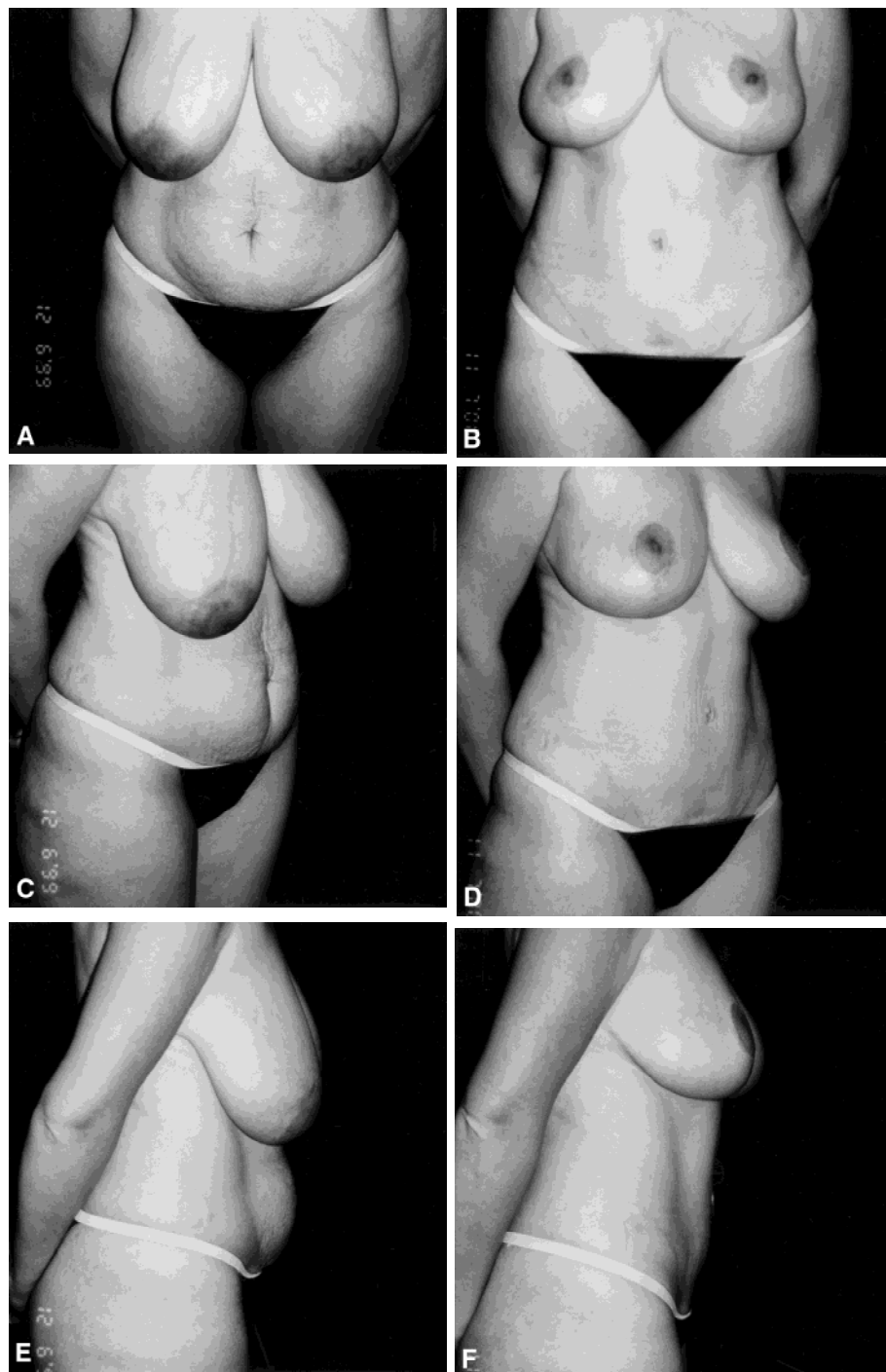


**Fig. 8.** Preoperative view (A, C) of a patient who presented with scar migration deformity after a previous abdominoplasty. Postoperative (B, D) views after correction with scar excision and anchor sutures to orient the scar more favorably while avoiding elevation of scar position or the pubic area.

thereby keep the final length of the scar as short as possible. A suction drain is placed crossing the midline. This is removed when drainage output is less than 30 cc in 24 hs, usually within 1–5 days. Prophylaxis against venous thromboembolism with intermittent pneumatic leg compression is also routine. The operation is done as an outpatient under epidural block anesthesia, with intravenous sedation. Patients are encouraged to ambulate as soon as they are able, and oral analgesics are adequate for pain relief.

### Review

A review of 111 consecutive patients who underwent either a standard abdominoplasty or mini-abdominoplasty was done, covering the time period when the technique described herein was developed and beginning prior to its use routinely. The operative technique was recorded with regard to use of anchor sutures, and the postoperative record was reviewed with any complications noted. For the purposes of this study, any case in



**Fig. 9.** Preoperative views (A, C, E). Postoperative views (B, D, F).

which percutaneous aspiration of fluid under the flap was required was recorded as a seroma.

**Results**

Adequate data was available on 110 patients, with follow-up from 1 to 42 months. Of these 110 patients, 80 had anchoring sutures utilized and 30 did not; the seroma rates were 6% and 33%, respectively (Table 1). Of the five patients in whom the anchor suture technique was used and who developed a seroma, one required two

**Table 1.** Effect of anchor suture technique on seroma formation.

	Total	Seromas	%
Full Abdominoplasty + Anchor Suture	70	4	
Miniabdominoplasty + Anchor Suture	10	1	
<b>Total</b>	<b>80</b>	<b>5</b>	<b>6</b>
Full Abdominoplasty – Anchor Suture	21	7	
Miniabdominoplasty – Anchor Suture	9	3	
<b>Total</b>	<b>30</b>	<b>10</b>	<b>33</b>

percutaneous aspirations in the office; the others resolved with a single aspiration. These five patients had anchor sutures in the midline only, and no seromas were observed in patients in whom midline and paramedian anchor sutures were utilized. Scar migration was not observed in any patient with anchor sutures along the line of closure. As an incidental finding, unexpected abdominal wall hernias were encountered in two patients, both in the upper midline and containing only omental fat.

## Discussion

Techniques for abdominal dermolipectomy have evolved significantly over the past three decades. The prototypical low transverse excision [6] is only rarely desirable now, having been replaced with a scar configuration which is low across the suprapubic area and angles obliquely in a superolateral direction. This allows for better contouring and incorporation of high lateral tension if desired [5]. The design described here emphasizes high central tension. The abdominoplasty scar is strategically placed so as to be concealable with swimwear and exercise attire to the extent possible. A concealable scar is often as important as improved contour, however, regardless of the length of the scar.

The progressive tension suture technique has been elegantly described by Pollock [7]. A variation emphasizing high superior tension has recently been reported by Le Louarn and Pascal [3]. These techniques derive from the method of quilting sutures which are designed to passively close off "dead space" [1], but differ in the emphasis on aiding in flap advancement by sequential allocation of tension. Either procedure may very well eliminate seromas altogether, without long-term drainage. Although the five seromas in patients with anchor sutures in this series were small and easily managed, avoidance of the need for long-term drains without increasing the risk of seroma formation is preferable. By minimizing the period of time with a drain in place, it is

also likely that the risk of infection will be extremely low while maximizing patient comfort.

The importance of the superficial fascia as a proxy for flap tension instead of the skin has been emphasized by Lockwood [4]. By using the superficial fascia for anchoring the flap, even a tight advancement should enable the skin edges to come together without tension. Incision and advancement of the rectus sheath [9] or musculofascial flaps [8] seem unnecessary as a routine, and likely to prolong recovery for some patients. Also, overcorrection is possible, resulting in an imbalance between the waist and hips, however, it may be of benefit in patients requiring more aggressive waistline contouring. Aggressive plication of the fascia is usually sufficient. A flexible approach utilizing a full palette of techniques including anchor sutures, sharp defatting, and deep fascial plication is the key to consistent results.

## References

1. Baroudi R, Ferreira CAA: Seroma: how to avoid it and how to treat it. *Aesthetic Plas Surg* **18**:439, 1998
2. Greminger RF: The mini-abdominoplasty. *Plast Reconst Surg* **79**:356, 1987
3. Le Louarn C, Pascal JF: High superior tension abdominoplasty. *Aesthetic Plas Surg* **24**:313, 2000
4. Lockwood T: Superficial fascia system (SFS) of the trunk and extremities: a new concept. *Plast Reconst Surg* **87**:1009, 1991
5. Lockwood T: High-lateral-tension abdominoplasty with superficial fascial suspension. *Plast Reconst Surg* **96**:603, 1995
6. Pitanguy I: Abdominal lipectomy: an approach to it through an analysis of 300 consecutive cases. *Plast Reconst Surg* **40**:384, 1967
7. Pollock H: Progressive tension sutures: a technique to reduce local complications in abdominoplasty. *Plast Reconst Surg* **105**:2583, 2000
8. Psillakis J: Plastic surgery of the abdomen with improvement in the body contour. *Clin Plast Surg* **11**:465, 1984
9. Ramirez O: Abdominoplasty and abdominal wall rehabilitation: a comprehensive approach. *Plast Reconst Surg* **105**:425, 2000